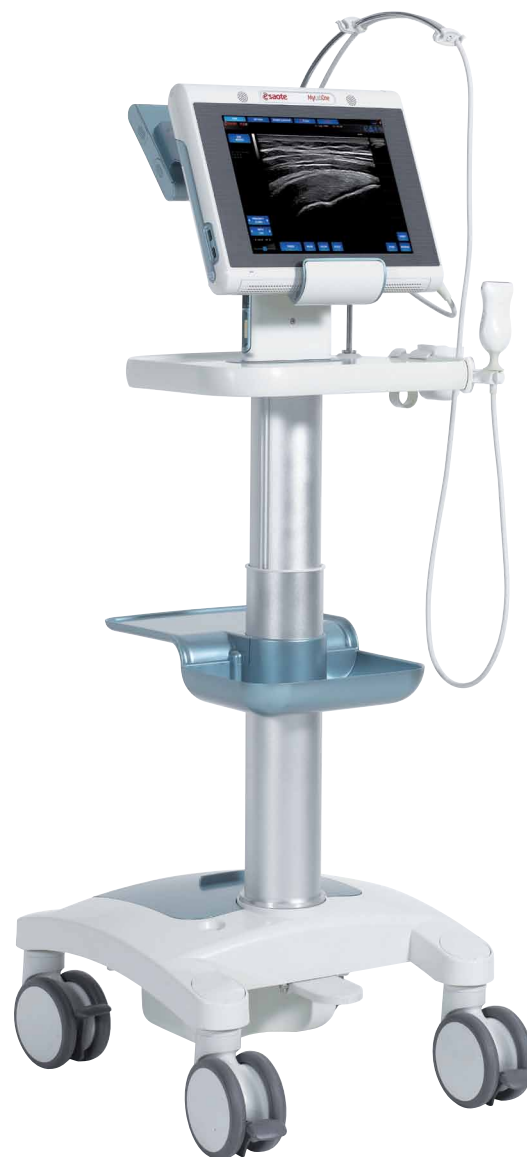
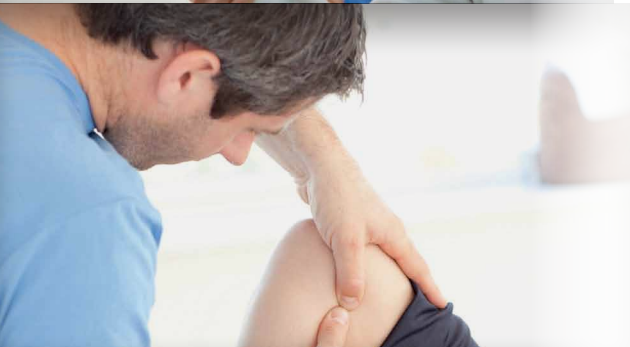
In touch with Physiotherapy



MyLabOne™
Musculoskeletal



- High-resolution and high-contrast imaging
- Simple and intuitive user interface
- Full touch screen
- High Sensitivity Color Doppler
- MyLibrary user reference guide
- Dedicated accessories and tools
- Wireless connectivity
- Dedicated ergonomics

Technologies

- **22 MHz XHF** Up to 22 MHz Transmission Frequency
- **XView** Image Enhancement
- **MView** Spatial Multi-View Imaging
- **TEI™** Tissue Enhancement Imaging

MyLibrary

SHOULDER

ELBOW

WRIST

HIP

KNEE

SUPRAPATELLAR BURSA

PREPATELLAR BURSA

INFRAPATELLAR BURSA

QUADRICEPS

INFRAPATELLAR TENDON

PATELLOFEMORAL JOINT

MEDIAL COLLATERAL LIG. & MED. MENISCUS

MEDIAL MENISCUS (DORSAL)

LATERAL MENISCUS (DORSAL)

COLLATERAL LIGAMENT

ANKLE

LONG TRANS

QUADRICEPS TENDON

Place the transducer in a longitudinal plane over the patella and quadriceps tendon with the knee in 90 degrees of flexion

Reference:

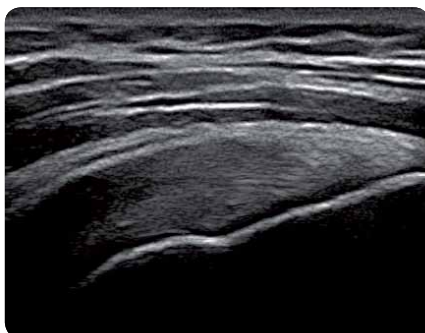- Patella
- Femur
- Suprapatellar bursa

Assessment:

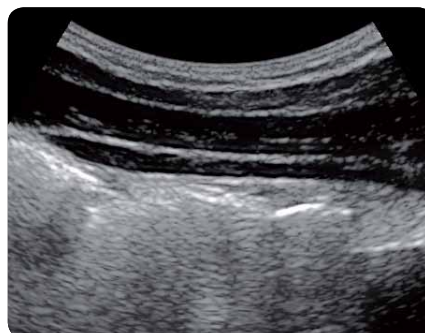- Fluid suprapatellar bursa
- Quadriceps tendon

1 Quadriceps tendon 2 Suprapatellar fat 3 Patella 4 Femur
5 Prefemoral fat pads 6 Patellar recess

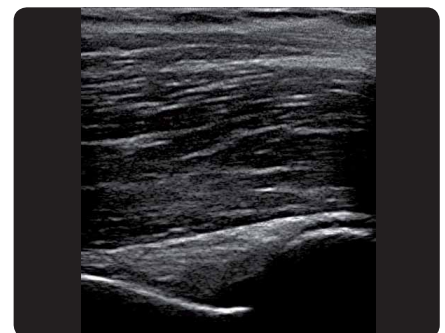
Made in cooperation with MSc Marc J.H. Schmitz, Physiotherapist, Manual therapist, Ultrasonographer. Kine Care, Roermond and Amsterdam, The Netherlands.



Shoulder, Longitudinal Supraspinatus Tendon



Obliques & Transversus Abdominis



Elbow, Longitudinal Coronoid Fossa

Probes range

